

Ultrasound of the ANKLE

Helen Keen

With some help from Emilio Filippucci!

US of the ANKLE

Indications

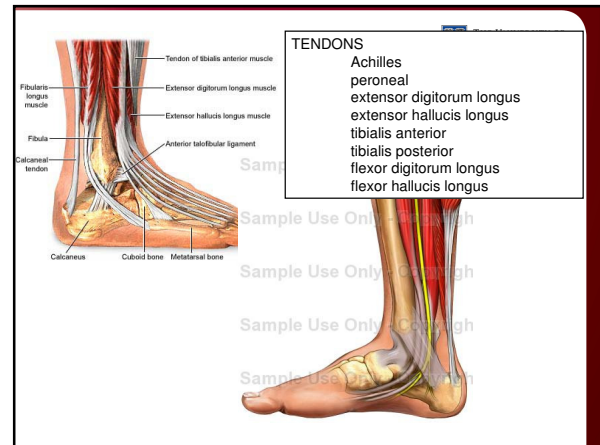
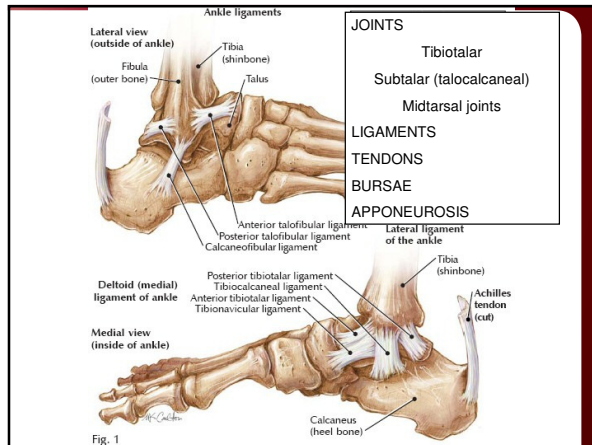
- Joint, tendon and enthesal involvement in patients with pain and/or swelling ankle and foot

Equipment

- High-quality machine
- High frequency probes: 6-18 MHz
- Doppler signal to assess vascularity

Scanning technique

- Multiplanar, bilateral and dynamic assessments
- EULAR guidelines on image acquisition
 - Backhaus M, Burmester GR, Gerber T, Grassi W, Machold KP, Swen WA, Wakefield RJ, Manger B; Working Group for Musculoskeletal Ultrasound in the EULAR Standing Committee on International Clinical Studies including Therapeutic Trials. Guidelines for musculoskeletal ultrasound in rheumatology. Ann Rheum Dis. 2001 Jul;60(7):941-9.



EULAR Guidelines on US of the ANKLE

Positioning of the patient

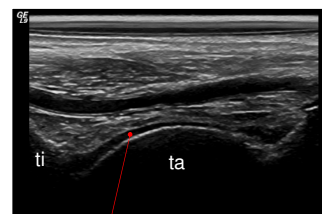
- Supine position for ventral and lateral scans
- Prone position for dorsal scan
- Hip and knee joints in neutral position

Standard scans

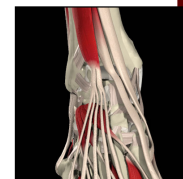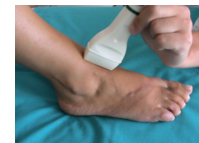- 1 Anterior longitudinal scan
- 2 Anterior transverse scan
- 3 Perimalleolar medial longitudinal scan
- 4 Perimalleolar medial transverse scan
- 5 Perimalleolar lateral longitudinal scan
- 6 Perimalleolar lateral transverse scan
- 7 Posterior longitudinal scan
- 8 Posterior transverse scan

Backhaus M, Burmester GR, Gerber T, Grassi W, Machold KP, Swen WA, Wakefield RJ, Manger B; Working Group for Musculoskeletal Ultrasound in the EULAR Standing Committee on International Clinical Studies including Therapeutic Trials. Guidelines for musculoskeletal ultrasound in rheumatology. Ann Rheum Dis. 2001 Jul;60(7):941-9.

Anterior longitudinal scan – Tibiotalar joint



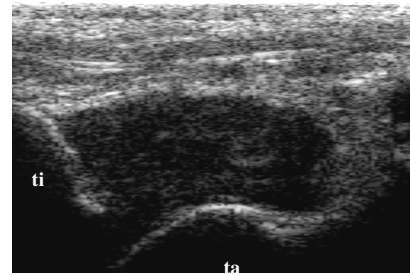
articular cartilage



US findings in OA of the ankle

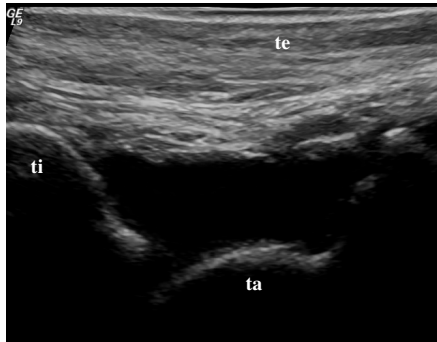
- Cortical bone changes
 - Osteophytes, irregular bone
- Cartilage changes
 - Thinning
 - Irregular
 - loss of normal anechoic echostructure
 - loss of clarity/sharpness of borders
- Synovial changes
 - Low level synovial proliferation +/- Doppler signal
 - Low level effusions

Anterior longitudinal scan – Tibiotalar joint



Proliferative synovitis

Anterior longitudinal scan – Tibiotalar joint



Exudative synovitis

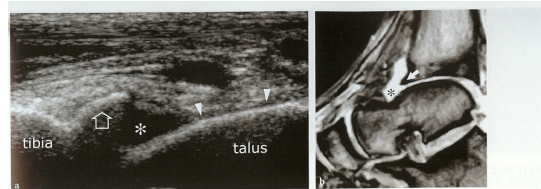
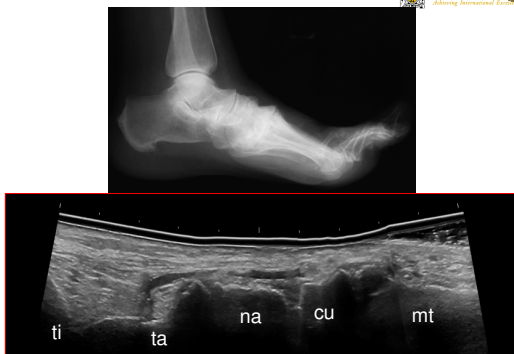

Fig.16.38 a,b. Anterior impingement syndrome. a Longitudinal 12-5 MHz US image with b T2*-weighted MR imaging correlation demonstrates a prominent spur (arrow) at the distal end of the anterior tibia. The spur is intracapsular in location and appears bordered by fluid (asterisk). During ankle movements, it remained still. Note the loss of the thin hypochoic layer of articular cartilage (arrowheads) that overlies the talar dome in comparison with Figures 16.13b and 16.17

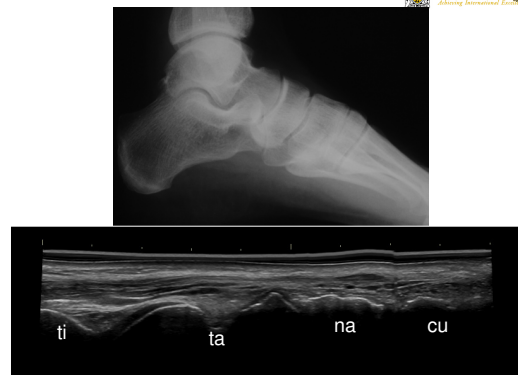Ultrasound of the Musculoskeletal System. Bianchi, S Martinoli, C

Anterior longitudinal scan – Tibiotalar joint



Osteophytes

Anterior longitudinal scan – Tibiotalar joint



US in ANKLE OA

- Benefits
 - Demonstrate subclinical changes
 - Identify/clarify the pathology
 - Guide injections
 - ?? Detect early disease
 - ?? Monitor therapy
- Limitations
 - Physical properties of sound
 - Unable to image subcortical bone
 - Acoustic window
 - Operator dependant
 - Quality of equipment
 - Aids diagnosis, not a diagnostic tool in itself