

Musculoskeletal Ultrasound: Osteoarthritis of the Elbow

NYU Hospital for Joint Diseases



Jonathan Samuels, MD
September 18, 2008
2008 World Congress on Osteoarthritis

Ultrasound of the Elbow

Helpful in the diagnosis of:

- Soft tissue pathology
 - epicondylitis and ligament injuries
 - biceps and triceps pathology
 - olecranon bursitis
 - ulnar nerve problems
- Synovitis, effusions and erosions in inflammatory arthritis
- Tophi vs. rheumatoid nodules
- Loose bodies and **osteoarthritis**



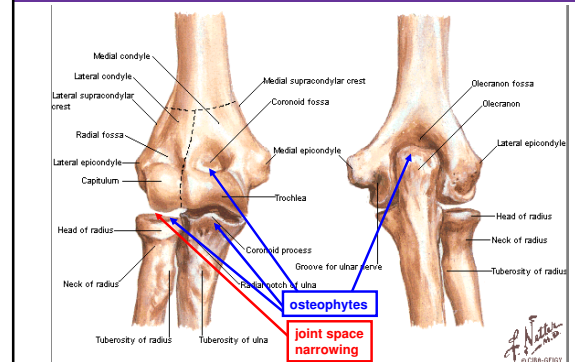
Osteoarthritis of the Elbow (Primary)

- Rare, with prevalence less than 2%
 - different from normal progression with aging
- Often associated with heavy use of the arm
 - more common in laborers, weight lifters and athletes who throw
- Pain, loss of extension
- Unlike OA of other joints Dalal S et al. J Shoulder Elbow Surg 2007;16: 358-61.
 - relative preservation of articular cartilage
 - relative maintenance of joint spaces



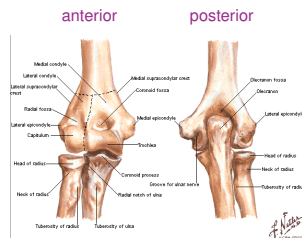
anterior

posterior



Elbow Ultrasound: 7 standard views

- Anterior
 - humero**radial** longitudinal
 - humero**ulnar** longitudinal
 - transverse
- Medial longitudinal
- Lateral longitudinal
- Posterior
 - longitudinal
 - transverse



Elbow Ultrasound: 7 standard views

- Anterior
 - humero**radial** longitudinal
 - humero**ulnar** longitudinal
 - transverse
- Medial longitudinal
- Lateral longitudinal
- Posterior
 - longitudinal
 - transverse

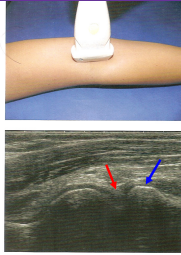
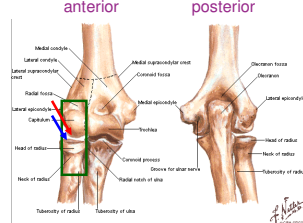
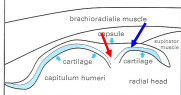
Many of the following ultrasound images are courtesy of:
Bruyn, G. Schmidt W. *Introductory Guide to Musculoskeletal Ultrasound for the Rheumatologist*. Bohn Stafleu van Loghum, 2006.

Areas more commonly showing OA will be marked with colored arrows

Probe placement will be marked on the **Netter images** by a green box

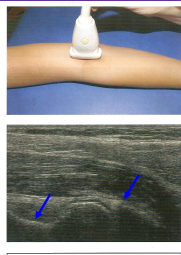
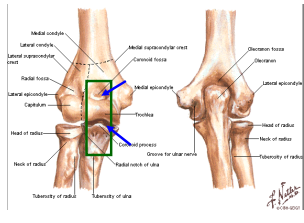
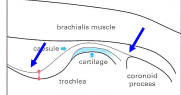


Anterior (1 of 3): Humeroradial Longitudnal

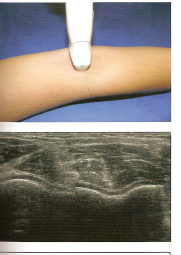
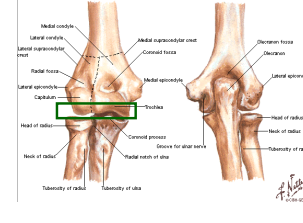

NYU Hospital for Joint Diseases
Langone Medical Center

Anterior (2 of 3): Humeroulnar Longitudnal

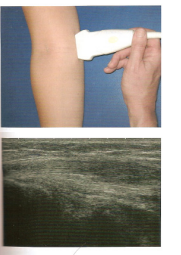
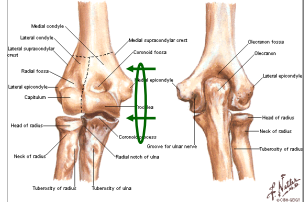
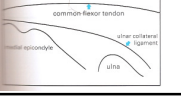
NYU Hospital for Joint Diseases
Langone Medical Center

Anterior (3 of 3): Transverse

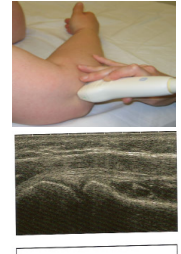
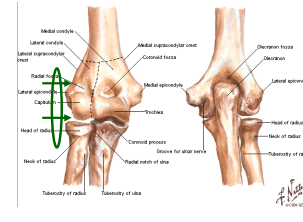
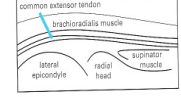
NYU Hospital for Joint Diseases
Langone Medical Center

Medial Longitudnal

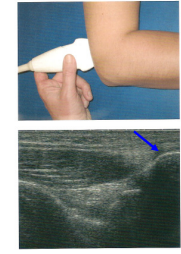
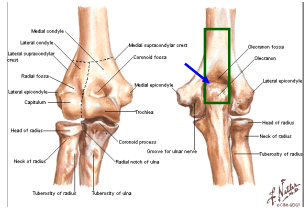
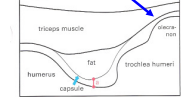
NYU Hospital for Joint Diseases
Langone Medical Center

Lateral Longitudnal

NYU Hospital for Joint Diseases
Langone Medical Center

Posterior Longitudnal

NYU Hospital for Joint Diseases
Langone Medical Center

Posterior Transverse

anterior posterior

NYU Hospital for Joint Diseases
Langone Medical Center

Sonographic findings in elbow OA

Loose body vs. osteophyte in coronoid fossa

Jacobson, JA. Musculoskeletal Ultrasound. Saunders Elsevier, 2007.

NYU Hospital for Joint Diseases
Langone Medical Center

Sonographic findings in elbow OA

Annular recess around neck of radius

Jacobson, JA. Musculoskeletal Ultrasound. Saunders Elsevier, 2007.

NYU Hospital for Joint Diseases
Langone Medical Center

Sonographic guidance of elbow injections

Can also aspirate/inject anterolaterally in semiflexion (less flexion than in this picture) between the radial head and lateral epicondyle.

Fessell, D. P. et al. Am. J. Roentgenol. 2000;174:1353-1362

NYU Hospital for Joint Diseases
Langone Medical Center

Conclusions

- In elbow OA,
 - osteophytes form near olecranon, coronoid, and radius
 - joint space narrowing is most common at the radiocapitellar joint
 - cartilage is generally well maintained vs. other joints with OA
- Ultrasound can be a helpful tool in the diagnosis of OA and other syndromes affecting the elbow

NYU Hospital for Joint Diseases
Langone Medical Center

Thank You

Which developed elbow OA first?

© 2006
Bryant G. Schmitz W. Introductory Guide to Musculoskeletal Ultrasound for the Rheumatologist. Beth Staflou van Loghum, 2006.
Daiji S et al. Radiographic changes at the elbow in primary osteoarthritis: a comparison with normal aging of the elbow joint. J Shoulder Elbow Surg 2007;16: 359-61.
Fessell, DP et al. Using sonography to reveal and aspirate joint effusions. Am. J. Roentgenol. 2000;174:1353-1362.
Jacobson, JA. Musculoskeletal Ultrasound. Saunders Elsevier, 2007.

NYU Hospital for Joint Diseases
Langone Medical Center